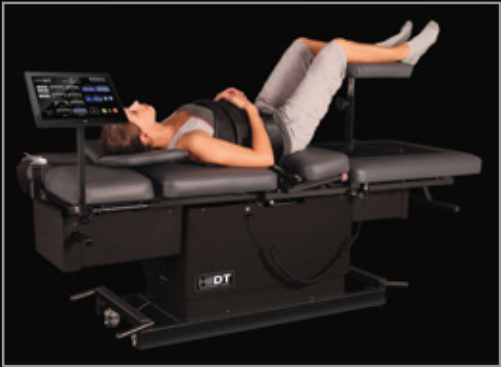

# Non-Surgical Management For Disc Pathology



**HiIDT**  
DECOMPRESSION THERAPY

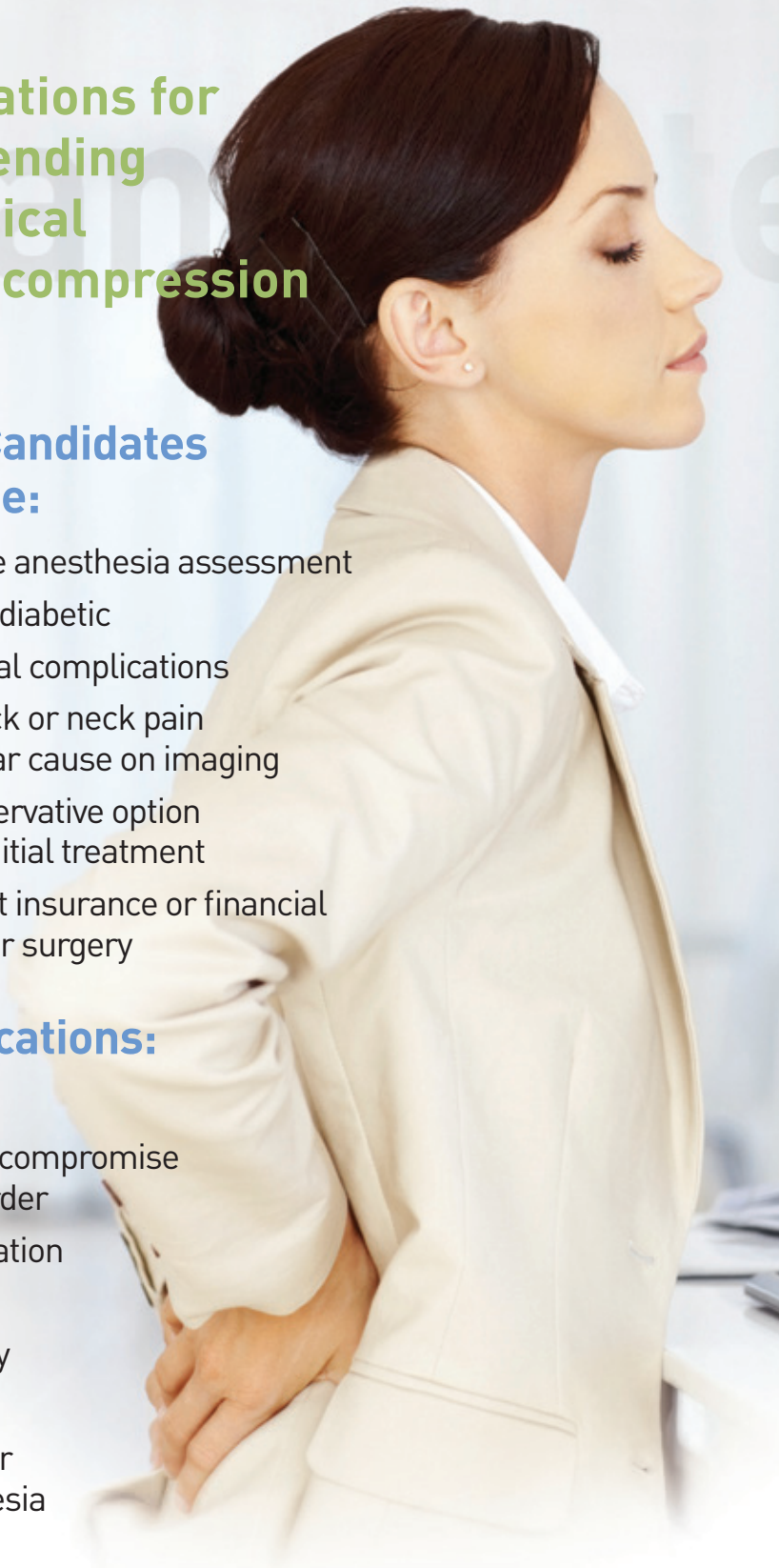
# Considerations for Recommending Non-surgical Spinal Decompression Therapy

## Potential Candidates may include:

- Cannot pass the anesthesia assessment
- Diabetic or pre-diabetic
- Previous surgical complications
- Chronic low back or neck pain without any clear cause on imaging
- Wanting a conservative option to surgery for initial treatment
- Patients without insurance or financial means to pay for surgery

## Contraindications:

- Malignancy
- Cardiovascular compromise or clotting disorder
- Fracture/dislocation
- Pregnant
- Spinal Instability
- Infection
- Cauda Equina or saddle paresthesia



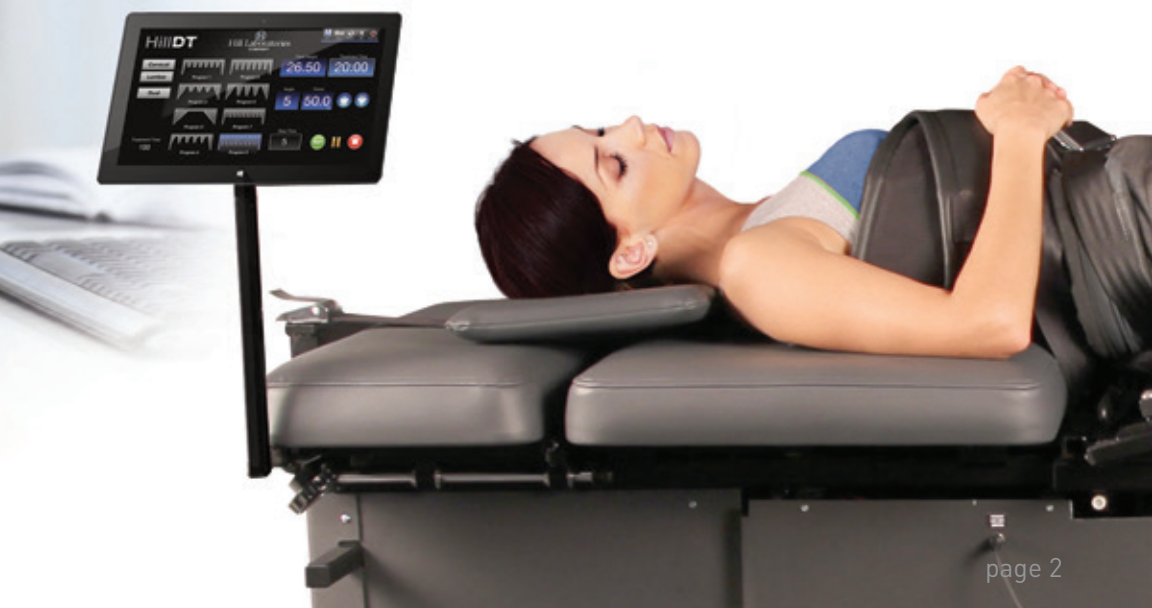# What is

# Spinal Decompression?

Non-surgical spinal decompression is a non-invasive treatment for a variety of neck and back conditions including:

- **Disc bulge/herniation**
- **Degenerative disc disease**
- **Degenerative joint disease**
- **Facet arthropathy**
- **Radiculopathy/radiculitis**
- **Sciatica**
- **Post-laminectomy syndrome**
- **Opioid addiction due to pain management**
- **Neck or back pain without a clear causation or positive findings noted on imaging**

These conditions benefit from restoration of the proper dynamics of the anterior motor unit of the spine, primarily the intervertebral disc. Through gentle, repetitive axial loading or distraction of the spine, a physiological change occurs at the disc space. This allows for rehydration of the disc and the surrounding tissues which assists the body's natural healing process.

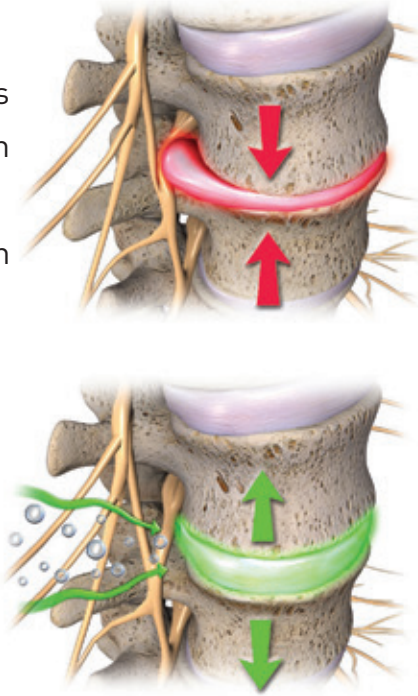


# How Spinal Decompression Works

## A Formula for Relief

Through the stretch and release protocols of the decompression procedure, negative pressure is created in the disc over time.

This vacuum effect draws any herniated disc material back into the disc.



## When Negative is Positive

By relieving pressure in the spine, increased circulation also occurs in the disc which is a vital aid in the healing process.

◀ Spinal illustrations provided by 3DRX Inc. [www.3drx.com](http://www.3drx.com)

## Disc Pressure Comparison



**Incorrect lifting**  
450%



**Correct lifting**  
200%



**Standing**  
100 % pressure



**Spinal Decompression**  
Negative Pressure

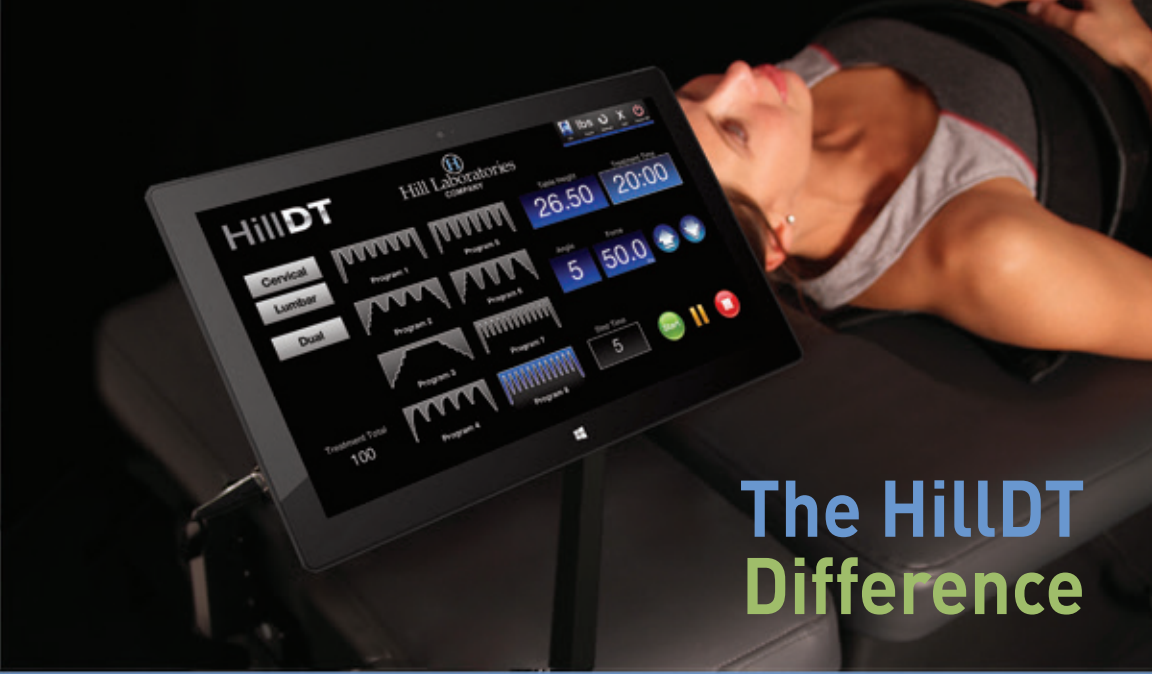

**Lying Down** 45%



**Traction Manipulation**  
30%



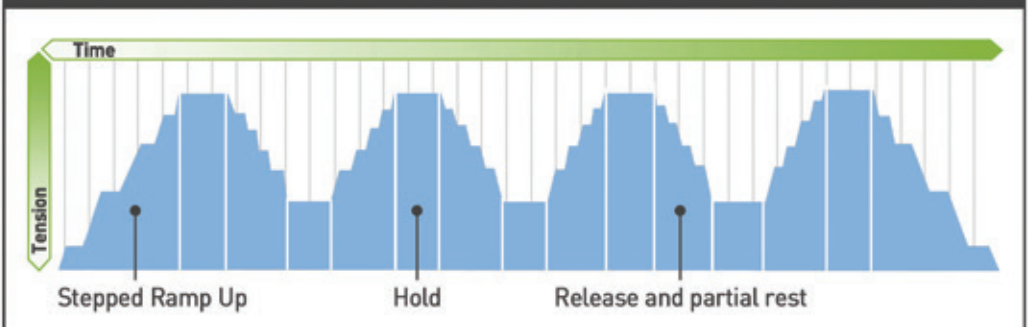


# The HillDT Difference

Decompression creates a vacuum or negative pressure which draws nutrients, oxygen and fluids into the disc.

The Hill DT table is unique in comparison to other treatment tables. But it's more than a table, it's a comprehensive program. The sensors in the table continually monitor the patient to ensure proper treatment is delivered. Nutrients and oxygen-rich blood are drawn back into the disc. Since these areas of the spine receive low circulation, this is a critical component of decompression.

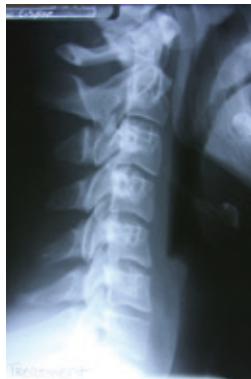## How Spinal Decompression works on the HillDT Table



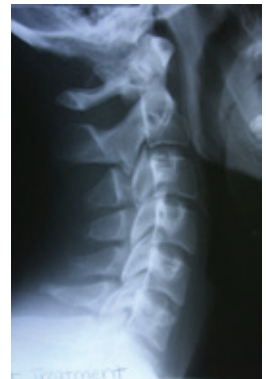# Case Study

## #1 18-year-old male involved in a motor vehicle accident suffering from significant neck pain, headaches, and bilateral parathesia.

Upon examination, he had a positive cervical compression test, restricted ROM in the cervical spine with significant trigger point pain identified at multiple sites in the cervical and upper thoracic spine. X-rays revealed a reversal of the normal cervical lordosis, paradoxical motion at the posterior, indicative of a sprain/strain or whiplash injury. Pain indices were noted at an 8-9 out of 10 for neck pain and a 5-6 out of 10 for headaches. The bilateral numbness was noted as intermittent and mild to slight.



Pre-Treatment



Post-Treatment

A 6-8 week treatment plan of chiropractic adjustment or CMT, exercise therapy or muscle rehab, and 8-10 visits of non-surgical axial spinal decompression using the Hill DT Decompression Table.

## Results

All of his symptoms abated within 4-6 weeks. Due to the significant level of improvement, a follow-up lateral cervical film was ordered to determine if additional rehabilitation would be indicated as ongoing support for postural improvement of the loss of the cervical curve. Upon re-evaluation it was noted however, that the patient had fully recovered from his symptoms. His ROM was normal, he had no positive orthopedic or neurological signs, and on x-ray his cervical spine had returned to the normal lordosis. Pre and post cervical films confirm the patient's structural correction.

## Summary

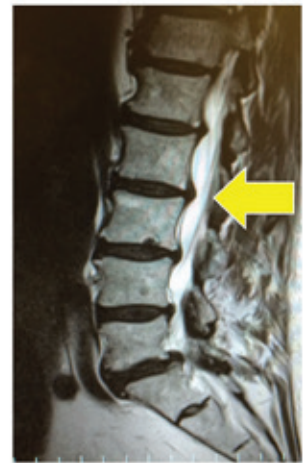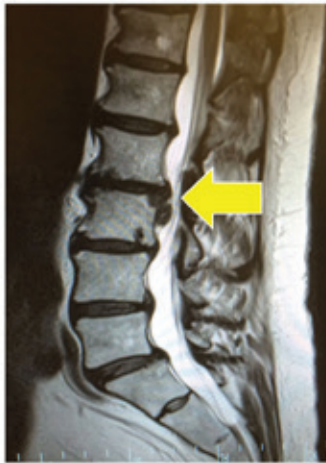**The Hill DT Decompression Table played an significant role in the patient's treatment plan. Complete restoration of a cervical lordosis after treatment can take months of rehabilitation in conjunction with CMT. The recovery time was greatly reduced by treatment with the HillDT.**

Case study authored by Timothy Burkhart, DC, BCIM


# Case Study

## #2 57-year-old male patient involved in a work related injury from repetitive lifting. The patient presented with severe mid to lower back pain and pain down the left leg.

MRI confirmed a significant disc herniation at L2/L3 and was recommended surgery. However, the patient declined to do the spinal surgery due to known adverse effects and sought spinal decompression therapy as his first option. Pain reduced from an 8 out of 10 to a 4 in 12 visits. After 24 visits, the patient returned to work with an average pain level of 1-2. After 36 decompression treatments in a several month period, a second MRI revealed a complete regression of the previously diagnosed disc herniation. The patient returned to work pain free and required no surgery.



### Results



MR OF THE LUMBAR SPINE WITHOUT CONTRAST

Study Information: MR LUMBAR SPINE WITHOUT CONTRAST

Exam Information: MR LUMBAR SPINE WITHOUT CONTRAST

Findings: L2-3: Interval regression of the large disc herniation seen previously extruding into the left lateral recess of L2-L3. No neural compromise is present.

L2-3: Interval regression of the large disc herniation seen previously extruding into the left lateral recess of L2-L3. No neural compromise is present.

### Summary

Results of spinal decompression were verified by the MRI.

Case study authored by Timothy Burkhart, DC, BCIM

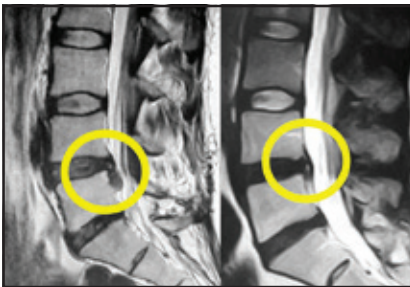
# Case Study

## #3

A 42-year-old female school teacher presented with severe low back pain radiating into her right leg. The severity of symptoms had her wheelchair bound. Surgical history included a discectomy at L5/S1 two years prior. Physical examination revealed signs of discogenic pain. MRI revealed a disc prolapse at L4-L5. The patient wanted to avoid another surgery at all costs due to the extended recovery associated with the last operation.

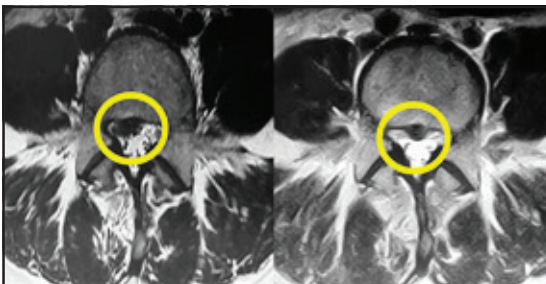
### Results

Non-surgical axial spinal decompression with physiotherapy was deemed to be the best alternative. She was able to walk without assistance from the wheelchair after 4-5 sessions. The pain indices improved from a complaint of 9 out of 10 to no pain by the 10th session. She returned to a full duty work after 12 sessions. Full recovery occurred within 24 sessions.



### Summary

Spinal decompression therapy is a viable alternative for patients that are unable or do not wish to undergo surgery. Prior surgical intervention does not contraindicate treatment.



The precision of the HillDT software and gentle pulling allows for effective treatment and an astonishing result.

Case study authored by Hani Azzouni, MD

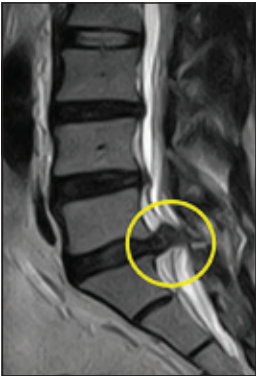

# Case Study

## #4

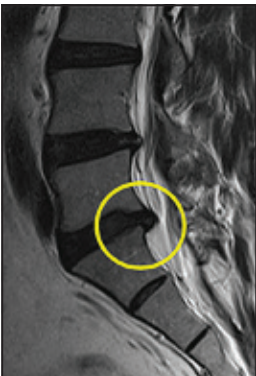
**40-year-old male presented with persistent low back pain for over 2 years. Sciatic neuralgia had developed in the past 6 months indicating decline in the patient's condition. He was unable to sit or stand for more than 3 minutes due to severe pain.**

Antalgic lean was noted and physical examination revealed weakness was noted ankle dorsiflexion and extension of the big toe. Other neurological signs included reduced patellar and Achilles DTRs. MRI revealed a disc extrusion at L5/S1. 6-8 weeks of spinal decompression was recommended with 1-2 co-modalities such as heat, electric stimulation, ultrasound and soft tissue mobilization.



### Results

Pain and claudication started to reduce after 10-12 sessions. Patient was able to resume normal daily activities with minimal pain and resolving neurological signs by the 22nd treatment. Ongoing rehabilitation included swimming sessions 2-3x per weeks to restore muscle strength and improve functional mobility of the back and leg. Remarkable improvement was noted in the patient's condition at the follow-up evaluation conducted 6 months after the initial visit. The patient was released from care in a pain-free state.




### Summary

**Spinal decompression therapy is a viable option for patients suffering from sciatica and long-standing low back pain. This case study supports the use of non-invasive axial decompression as management for disc conditions, even in cases of severe disc extrusion. The remarkable outcome for this patient, for which surgical intervention would have been the only other option due to longstanding pain and positive neurological signs, denotes the importance of exhausting conservative treatment options prior to more invasive treatments.**

Case study authored by Hani Azzouni, MD

“Treating patients in my Neurology practice with the HillDT spinal decompression system has improved my outcomes dramatically. Patients are consistently getting better and love the fact that the treatment is natural and drug free. Most importantly, it is the best treatment to promote healing of the disc and facets. Thank you HillDT!!!”

**Alexander Smirnoff, M.D.**



“As a conservative treatment option Non-Operative Decompression with the Hill DT has improved outcomes for procedures like epidural injections and has reduced or eliminated our patients need for oral pain medication.”

**Hsiu-Hsien (Tom) Ling, M.D.**

“The HillDT Table has been a tremendous addition to my practice. We are seeing dramatic improvement in disc herniation cases, including some that I thought would need surgery. We also see great response with headaches associated with neck pain and low back pain associated with severe arthritis.”

**David Teitelbaum, D.O.**



“Our Outcome Assessments show we are helping herniated and degenerated disc patients at an awesome success rate. The HillDT Spinal Decompression table gets results and I can't imagine practicing without it.”

**Randy Reed, D.C., C.C.S.P.**

“Since integrating decompression into our practice, our patient results have been amazing. Our clinical outcomes consistently provide significant patient improvement. This equipment works... the patient's results speak for themselves.”

**Timothy Burkhart, D.C., B.C.I.M., D.A.A.I.M.**



## Scientific research proves that decompression works.

### Chiropractic Economics (Vol.61, No. 4, March 13, 2015)

#### Measured Success, Evaluating the Effectiveness of Spinal Decompression Therapy

CONCLUSION: Of 815 patients receiving spinal decompression therapy a random selection revealed a 91% success rate” Davenport University 2015.

### Disc Distraction Shows Evidence of Regenerative Potential in Degenerated Intervertebral Discs, SPINE 2006

#### Disc repair fundamentally depends on the stage of disc degeneration

CONCLUSION: This study with respect to previous reports, confirms that disc distraction enhances hydration in the degenerated disc and may improve disc nutrition via the vertebral endplates. Thorsten Guehring, MD, et al; Department of Orthopedic Surgery, University of Heidelberg, Germany. SPINE (Vol. 31, Number 15, 2006)

### Journal of Neurologic Research (Vol. 29, No. 3, March 2003)

#### Efficacy of Vertebral Axial Decompression on Chronic Low Back Pain

CONCLUSION: This 144 patient study showed 76% achieved remission of pain. Except in emergent conditions, Vertebral Axial Decompression should be used on all conditions before surgery is undertaken.

### Orthopedic Technology Review (2003; 6 (5))

#### Surgical Alternatives: Spinal Decompression

CONCLUSION: 86% of the 219 patients who completed the therapy reported immediate resolution of symptoms, while 84% remained pain-free 90 days post-treatment. Physical examination findings showed improvement in 92% of the 219 patients, and remained intact in 89% of these patients 90 days after treatment. It was shown to be effective for herniated and degenerative discs.

### American Journal of Pain Management (Vol. 7, No.2, April 1997)

#### Decompression, Reduction, and Stabilization of the Lumbar Spine: A Cost Effective Treatment

CONCLUSION: Eighty six percent of herniated intervertebral disc patients achieved ‘good’ (50-89% improvement) to ‘excellent’ (90-100% improvement) results with decompression. Sciatica and back pain were relieved. Facet arthrosis patients, 75% obtained ‘good’ to ‘excellent’ results with decompression.

## Decompression Therapy has lasting results.

### Archives of Physical Medicine and Rehabilitation Medicine February 2008

#### Protocols for Patients with Activity – Limiting Low Back Pain

A total of 296 patients with low back pain and evidence of a degenerative and or herniated disc at 1 or more levels were in this study. 8 Week course of treatment consisting of 5, 30 minute sessions of Decompression Therapy per week for 4 weeks and 1, 30 minute session for a week for 4 additional weeks.

CONCLUSION: Patients showed continued statistical improvement in both pain scores and functional movement scores after their treatment programs were completed for 180 days post-treatment.

### Anesthesiology News, (Vol. 29, No. 3, March 2003)

#### Vertebral Axial Decompression Reduces Chronic Discogenic Low Back Pain-4 Year Study

CONCLUSION: Four year follow-up after Decompression method shows a sustained 86% reduction in pain and that 91% of patients had resumed their normal activities and has remained pain free.

## **Scientific research proves that decompression works.**

### **Journal of Back Musculoskeletal Rehabilitation, (Vol 30, No. 5, 2017)**

#### **A double-blind randomized study was performed in 2017**

As is common with NSD, other physiotherapy modalities were used. Both control and randomized groups received a combination of electrotherapy, deep friction massage and stabilization exercise for fifteen sessions. Improvement and disc regression were noted in both groups after 3 months. The NSD group had greater disc regression, but it was not significant with this study ( $P \rightarrow .05$ ). A more significant regression would likely have been noted if the industry standard of 20-30 treatment sessions were performed.

### **Spine (Vol 15. No. 32, 2007)**

#### **Research conducted by Fritz et al. indicates a certain subgroup must be considered when selecting low back cases for non-surgical decompression therapy.**

Certain pre-disposing factors such as the presence of both neck and back pain, involvement of third-party payers, and patient demographics may inherently limit the outcome. Subgroup selection is generally agreed to be less of a factor when considering neck pain.

Non-surgical spinal decompression an effective physiotherapy modality for neck and back pain (Vol. 4, No. 3, 2017).

Large retrospective study that supports a high success rate when patients are properly screened. The presence of control and sham cannot be performed in this setting, but the large sample sizes may be considered. Cervical and lumbar cases, of 209 individuals had a 80-90% improvement with non-surgical spinal decompression therapy.

**[www.HillDTSolutions.com](http://www.HillDTSolutions.com)**

Phone - 616-813-9370

Email - [info@HillDTSolutions.com](mailto:info@HillDTSolutions.com)

**President**

Jeff VanderWal

Email - [Jeff@HillDTSolutions.com](mailto:Jeff@HillDTSolutions.com)



Copyright © 2019 HillDT Solutions. All rights reserved. [www.hilldtsolutions.com](http://www.hilldtsolutions.com)